



This case report demonstrates the usefulness of PURINA® PRO PLAN® VETERINARY DIETS DRM Dermatitis in the nutritional management of Canine Atopic Dermatitis

A case of Canine Atopic Dermatitis in a 14-month-old female French Bulldog

Dr Xavier Langon

Clinique Vétérinaire de Camargue
34400 LUNEL – FRANCE

Details and case history

A 14-month-old female French Bulldog ("Lixy") was brought in for a consultation for pruritus, erythema, and crusts that had developed since the age of 6 months (Photo 1). The animal lives in a house with no other dogs and is fed commercial Veterinary Diet Dog Hypoallergenic Small Dog dry food. Its vaccinations were up to date and the patient had received proper internal and external antiparasitic treatment. She had no history of disease apart from the dermatosis for which she was brought in for examination. From the age of 6 months, the animal had been developing pedal and facial erythematous and pruritic dermatologic lesions, sometimes crusted in the axillae. Her owner did not report any lesions bothering her.



Photo 1 – General appearance of the patient

Physical exam

The animal's general condition was good and she had a healthy weight of 9.65 kg. The dermatosis was characterised clinically by marked erythema in the periorbital areas and on the pinnae, the whisker pads, and the dorsopalmar surfaces of all four feet, together with papules and crusts in the axillae. Mild lichenification at the base of the left auricular concha and in the periorbital region, moderate alopecia on the palmar surface of the carpi, more marked in the periorbital area, and dermatitis in the nasal folds combined with significant lachrymation making the facial intertrigo worse were also observed (Photos 2 and 3). The pruritus was intense, persistent and observed during the consultation. No trace of parasitism by fleas was noted.

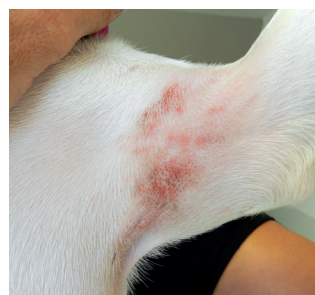

Photo 2 – Close-up view of the lesion in the left axilla.

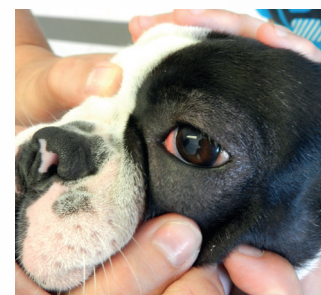

Photo 3 – Close-up view of the left blepharitis.

Differential diagnoses

The symptoms and history suggested several hypotheses: canine atopic dermatitis, demodicosis, dermatophytosis, superficial pyoderma or *Malassezia* dermatitis.

Additional examinations

Microscopic examination of skin scrapings did not reveal any parasites. Skin tests with adhesive tape revealed only occasional populations of *Malassezia* on the facial intertrigo. Microscopic examination of the product of external ear canal swabbing did not reveal any bacteria or yeast. The trichogram did not show any abnormalities in the hair growth cycles. A Wood's lamp examination proved negative and fungal culture allowed no mycelial colony growth.

PURINA
PRO PLAN
VETERINARY
DIETS

Diagnosis

The history, clinical signs, and additional tests' results led us to consider a diagnosis of **Canine Atopic Dermatitis**. Following the consultation, Lixy was shown by intradermal skin testing to be sensitive to the airborne allergens *Dermatophagoïdes farinae*, *Tyrophagus putrescentiae* and *Lepidoglyphus destructor*. We agreed with the owners to perform a diet change trial with Canine Dermatitis DRM food to manage the dermatosis.

Therapeutic management and follow-up

In order to best judge the therapeutic efficacy of the new diet, in agreement with the owners, no change other than the alteration in diet was prescribed given that the pruritus was "bearable" despite the presence of lesions. The dietary transition took place over 1 week, then Lixy was kept on the diet strictly for 2 months. Her progress was monitored monthly.

After the first month of follow-up, a deterioration in the dermatosis was observed, together with worsening of the blepharitis, cheilitis, inflammation of the pinnae and lesions in the large folds, and the onset of erythematous crusted lesions on the chin together with an increase in hair loss (photos 4 to 7). Additional skin tests were carried out but were unremarkable. No external parasites were observed. Lixy did not generally eat the food with enthusiasm, but it was digested well. In order to comply with the trial conditions, and to determine the role of the food versus a possible seasonal increase in environmental allergens, a joint decision was reached between the owner and the dermatologist not to intervene medically with respect to this unfavourable progression. The diet change trial was continued.

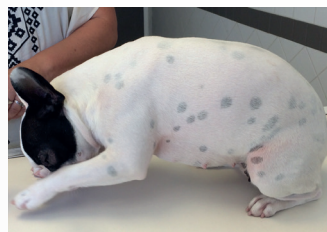

Photo 4 – Overview of the animal. Note the onset of a lesion in the stifle fold.

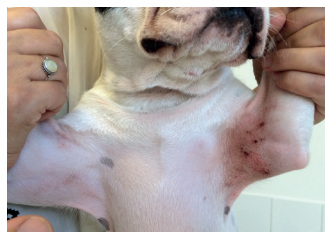

Photo 5 – Overview of the ventral surface of the thorax. Note the worsening of the axillary lesions

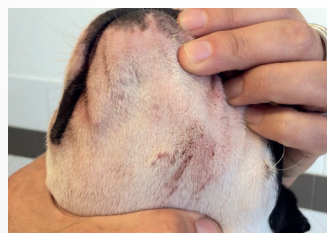

Photo 6 – Close-up view of the ventral surface of the head. Note the onset of a submandibular lesion




Photo 7 – Rostral view of the head. Note the worsening of the blepharitis and cheilitis

At the end of the second month, the pruritus was less severe, the blepharitis lesions had faded and the axillae appeared healthy. Lixy had mild erythema on the pinnae and whisker pads and moderate pododermatitis on all four feet (Photos 8 to 10). The owners were thoroughly satisfied with the favourable outcome and stool quality, despite the dog's lack of enthusiasm when eating the food (although she lost no weight over the 2 months).

This partial resolution, or at least improvement, achieved just by using this food as opposed to the other food under the same conditions, is a "natural" benefit for Lixy's dermatosis.

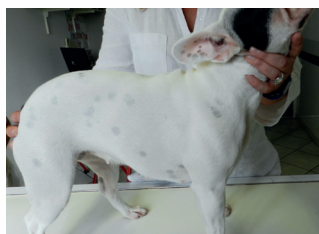

Photo 8 – General appearance of the patient. Note the dermatological improvement

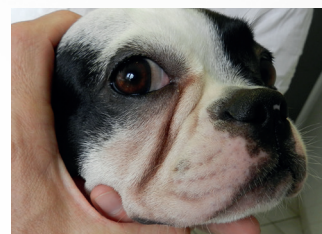

Photo 9 – Rostral view of the head. Note the reduction in the erythema.

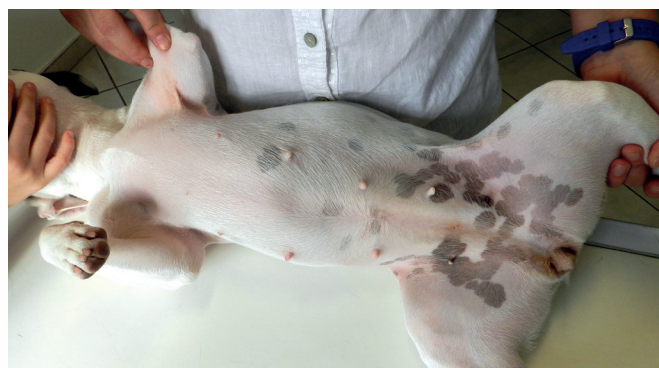

Photo 10 – Overview of the ventral surface. Note the clinical cure

Discussion and conclusion

This clinical case shows the value of using Canine Dermatitis DRM food for dermatosis, in particular canine atopic dermatitis. The composition of this product (when fed exclusively) led to a reduction in clinical signs.

In our trial, this food appeared particularly effective compared to the old food, and in the absence of any medication. Note, however, that because this animal is sensitive to mites, the change in season may have had a partial impact. It is also possible that the synchronism between the dog's dermatological relapse and poor enthusiasm for this new food is a joint digestive and cutaneous expression of Lixy's mite sensitivity.

In addition to its notable efficacy, Canine Dermatitis DRM proved to be easily digested, better than the foods previously used, as attested to by the owner due to the disappearance of flatulence. Regarding food intake, considered difficult by the owner, closer examination of Lixy's feeding behaviour revealed that the dog had eaten the new food perfectly well for the first 15 days, after which she ate it all but with little enthusiasm due to the dry food's kibble size. Lixy had in fact gobbled down her previous "small dog" food, and after the first 15 days of being excited about discovering a new flavour was put off by the need to chew before swallowing. This feeding behaviour was confirmed by another comment made by the owner: the dog no longer hiccupped on this new diet, whereas she had always done so when gobbling up the small dry food. Product palatability was therefore good.

Clearly, additional studies are needed to confirm the positive results obtained for Lixy.

In conclusion, this diet is recommended for long-term management of dermatoses such as canine atopic dermatitis.